



Institute of
Biomedical Science



The Royal College of Pathologist
Pathology: the science behind the cure

Diploma of Expert Practice in Histological Dissection

Examination 2022

Paper 1

Mandatory modules short-answer questions

120 minutes

1. Attempt **all** questions
2. Questions may be answered in any order
3. Each question is worth a total of 20 marks
4. You must transfer your answers directly into the answer booklet
5. Begin each new answer on a new page

The question paper is not to be removed from the examination room

Q1. Clinical Governance

- a. Describe **six** elements of specimen dissection where consideration of the risks involved must be made and suggest ways of mitigating against them whilst carrying out the dissection process. (12 marks)

- b. There are two permissible exposure limits for formaldehyde in the workplace, name them and what is the permissible level with each. (4 marks)

- c. You have received a sample with a different label on form and pot. What would you do? (4 marks)

Q2. General Principles of Specimen Dissection

- a. What is the importance of weighing some specimens at the dissection bench? (2 marks)

- b. Why do some specimens not need to be weighed? (2 marks)

- c. How do we ensure that the weight of specimens is accurate? (4 marks)

- d. What steps would you take at the dissection bench to ensure that small tissue samples are safely contained within their cassette before processing? (6 marks)

- e. What would you do if at embedding, the tissue sample was found to be missing from the cassette? (6 marks)

Q3. Surgical Procedures

What procedures may be used to take specimens from the following four sites and what factors influence the clinicians' choice? (5 points per site)

- a. Skin
- b. GI tract
- c. Cervix
- d. Breast

Q4. Pathological Processes

Atherosclerosis

- a. What are the major risk factors for development of atherosclerosis?
(4 marks, half mark for each factor mentioned)
- b. Briefly describe an atherosclerotic plaque. (2 marks)
- c. How does the presence of a plaque lead to vascular complications? (4 marks)

Atrophy

- d. Define atrophy. (2 marks)
- e. Briefly describe **four** causes of atrophy, with examples.
(8 marks – 2 for each cause and example)

Q5. Anatomical Nomenclature

- a. Draw an anatomical diagram of the kidney in the coronal plan labelling the key features.
(8 marks)
- b. Give the anatomical relationship of: (1 mark each)
- i. Abdominopelvic cavity to diaphragm
 - ii. Trachea to thyroid
 - iii. Patella to femur
 - iv. Right nipple to median
- c. Define the following anatomical terms or structures. (2 marks each)
- i. Glabella
 - ii. Anatomical position
 - iii. Lateral canthus
 - iv. Acetabulum



The Royal College of Pathologist:
Pathology: the science behind the cure

Diploma of Expert Practice in Histological Dissection

Examination 2022

Paper 2

Optional modules short-answer questions

120 minutes

1. Attempt 6 from 11 questions
2. Each question is worth 20 marks
3. You must transfer your answers directly into the answer booklet
4. Begin each new answer on a new page
5. Questions can be answered in any order

This question paper is not to be removed from the examination room.

Q1. Endocrine

You receive a total thyroidectomy with a clinical history of Graves' disease.

a. Provide a definition of Graves' disease. (2 marks)

b. How would you describe, handle and dissect this specimen? (8 marks)

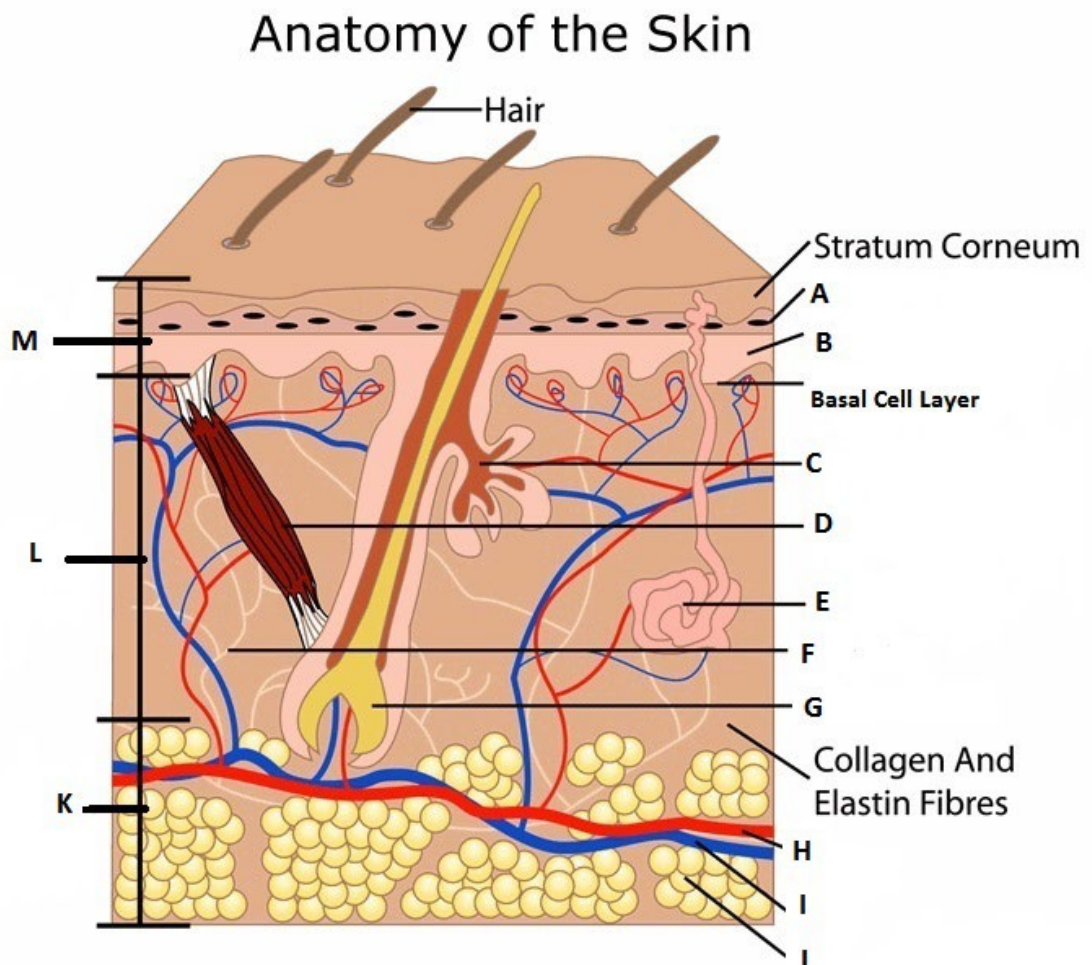
A clinician requests a CT scan on a 63 year-old patient. This shows a 2 cm mass in the right adrenal gland.

c. Briefly discuss the differential diagnoses of such a mass. (8 marks)

d. What other information or tests may help the clinician make a diagnosis? (2 marks)

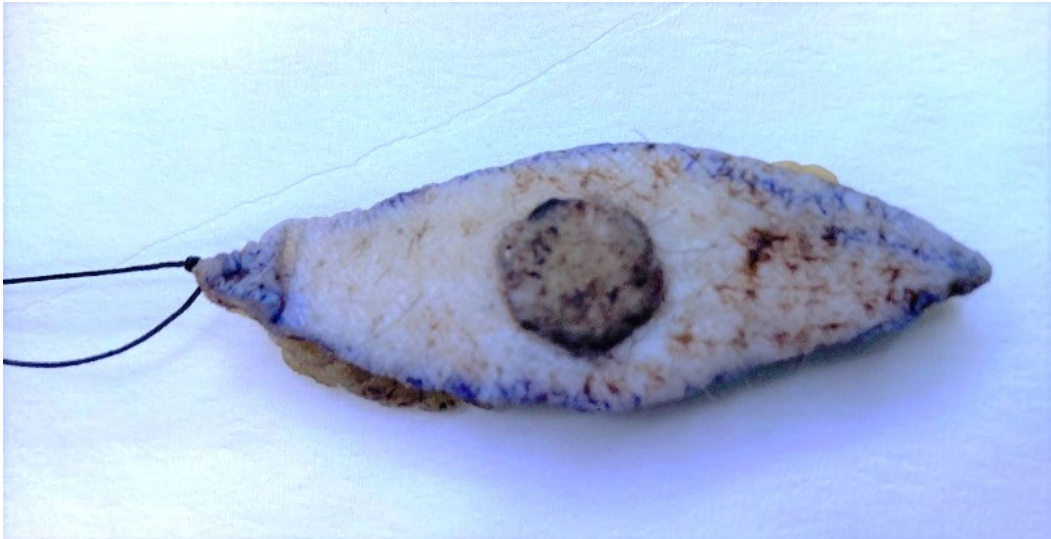Q2. Skin

a. Name the components and structures (A to J) and layers (K to M) shown in the schematic diagram of skin shown below. (7 marks)



... Question continues on next page

- b. Write short notes on the clinical and histological findings seen in dermatitis herpetiformis. (5 marks)
- c. You receive a 50 x 15 x 7 mm skin biopsy from a 50 year old male (photograph below), with clinical history of ?SCC on back. No indication given of suture orientation provided. How would you dissect this specimen? (4 marks)



- d. Some Squamous Cell Carcinomas are reported as High Risk. What clinical and histological features are high risk? (4 marks)

Q3. Breast

- a. Explain how you would prepare, handle, describe and sample a breast reduction specimen. (8 marks)
- b. Describe four lesions that may be encountered in breast reduction tissue and their typical macroscopic appearances. (4 marks)

A 51-year old lady presented with unilateral blood stained nipple discharge. Physical examination and imaging revealed no evidence of a mass lesion.

- c. What would be the differential diagnosis at this stage? (2 marks)

A subsequent excision specimen was received in the form of a total duct excision.

- d. Describe the classical macroscopic appearance of such a specimen. (2 marks)
- e. Describe how and why you would handle and dissect the specimen. (4 marks)

Q4. Osteoarticular and Soft Tissue

- a. Draw a labelled diagram of a synovial joint and write short notes on the functions of the different components. (10 marks)
- b. Give examples of four pathological conditions which commonly occur in association with joints. (4 marks)

A synovial biopsy is received in the laboratory to investigate joint disease.

- c. Outline the laboratory protocol for handling such a specimen and any further investigations which may be required. (6 marks)

Q5. Cardiothoracic

A 40 year old male presents with unexplained new-onset heart failure (HF) of less than 2 weeks duration associated with a normal size heart on ultrasound scan.

- a. Why may an endomyocardial biopsy be performed? (4 marks)
- b. Ideally what stains/procedures would you use to assess endomyocardial biopsies? (16 marks)

Q6. Gastrointestinal and Hepatobiliary

You receive a right hemicolectomy specimen with the clinical details of benign inflammatory mass at caecal pole. Macroscopically there is a bulky mass of congested fibrofatty tissue with an irregular external surface, covered with a fibrinous exudate associated with the exterior of the caecum and the appendix.

There are no macroscopically visible lesions or polyps within the small or large bowel mucosa. There is no history of inflammatory bowel disease.

- a. What dissection pre-treatment would you carry out on receipt of this specimen? (2 marks)
- b. What is the most likely cause of this inflammatory mass and what might you expect to see macroscopically when you slice into the mass. (3 marks)
- c. What blocks would you take from this specimen and why? (5 marks)
- d. What features might you see associated with the appendix which may raise concern that this is not a benign process and what action would you take? (3 marks)

You receive a TAMIS resection for a large villous surfaced “carpet” polyp 38 x 42mm x 13mm depth of the rectum. The specimen is pinned to a sponge board, with orientation indicated for 12 and 6o’clock. The previous biopsies of this lesion diagnosed a villous adenoma with low grade dysplasia.

- e. Discuss your key considerations in handling and dissection this specimen? (7 marks)

Q7. Gynaecological

You receive a Uterus and Cx specimen with the clinical information of fibroids. The specimen has been bisected in the sagittal plane to aid fixation by the surgical team. The cut surface shows a 63mm well circumscribed subserosal leiomyoma with a pale whorled surface. There is also a light brown endometrial polyp in the fundus 18 x 9 x 9mm. The ovaries are macroscopically unremarkable and there are some small paratubal cysts.

- a. Describe what blocks you would take and why? (4 marks)

You receive a specimen with the clinical details of molar pregnancy / hydatidiform mole.

- b. What are the causes and genetic differences between a complete and partial molar pregnancy? (4 marks)

- c. What are the essential descriptors to include in macroscopy of this specimen and what blocks would you take from this sample and why? (4 marks)

You receive a specimen pot and request form labelled bilateral prophylactic salphingo-oophorectomy for BRCA mutations.

- d. What is the clinical reason for carrying out this surgical procedure? (2 marks)

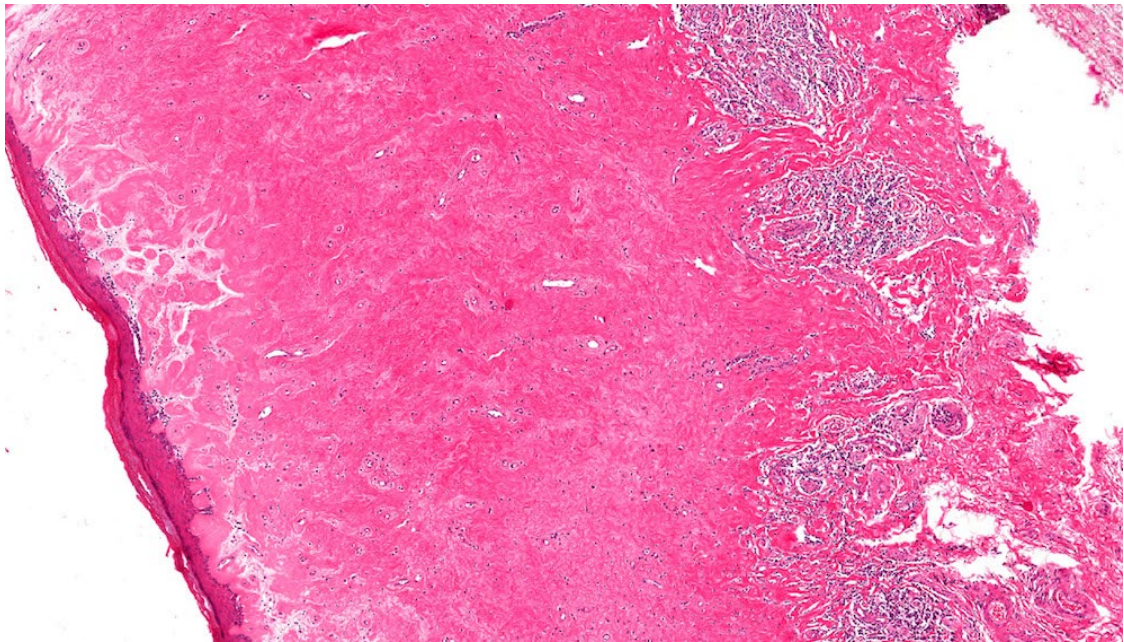
- e. What are the essential descriptors to include in macroscopy of this specimen, how you would dissect these specimens and block taking protocol? (5 marks)

- f. What is the clinical reason for carrying out this sampling protocol? (1 mark)

Q8. Genitourinary

Foreskin

- a. Define balanitis and explain how this may present clinically? (1 mark)
- b. A 30 year old male who went to the urologist with a history of untreated phimosis from childhood. Circumcision is performed, describe how you would dissect these specimens. (4 marks)
- c. At reporting the following image is seen, what is your diagnosis and why? (3 marks)



Kidney

- d. Define nephrotic syndrome. (1 mark)
- e. Briefly describe the key steps and considerations in handling a medical renal biopsy in the laboratory. (6 marks)
- f. Give three causes of chronic pyelonephritis. (3 marks)
- g. What is xanthogranulomatous pyelonephritis? (2 marks)

Q9. Haematolymphoid

- a. Describe the structure of a lymph node and its key anatomical structures. (6 marks)

A sentinel node is received in the laboratory.

- b. What is a sentinel node? (2 marks)
- c. Discuss the dissection and handling of sentinel nodes in the laboratory. (5 marks)
- d. Describe a clinical situation a sentinel node excision would be performed and the advantage over other techniques. (2 marks)

A patient presents with enlarged node in the axilla.

- e. A Block dissection is received in the laboratory. How is this treated? (5 marks)

Q10. Neuromuscular

- a. Describe the location and function of the following areas of the brain and brainstem. (2 marks each)
- i. Occipital lobe
 - ii. Hypothalamus
 - iii. Hippocampus
 - iv. Thalamus
 - v. Anterior commissure

You receive a specimen on the neuropathology dissection bench comprised of multiple fragments, in aggregate 8mm, with the clinical history 'posterior fossa tumour for frozen section and pathology'.

- b. How would you handle this specimen? (10 marks)

Q11. Head and Neck

A 62 year old male diagnosed with oesophageal adenocarcinoma is being investigated with a PET CT scan that shows an abnormal area in his left tonsil.

- a. How may this be investigated further? (4 marks)
- b. This patient's tonsil was removed. Describe the handling, dissection and block selection of this specimen. (6 marks)
- c. Discuss the need to send all tonsils for histological examination. (4 marks)

A specimen described as 'cyst' from the upper left 8 region is sent to the laboratory for processing.

- d. Discuss the possible macroscopic appearance of the specimen. (6 marks)