



**Higher Specialist Diploma**

**Medical Microbiology**

**Examination – September 2023**

Short-answer questions

60 minutes

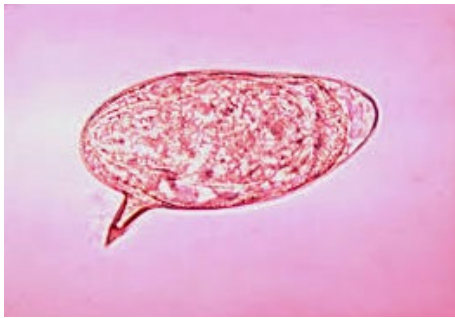**Attempt all four questions**

Instructions to candidates

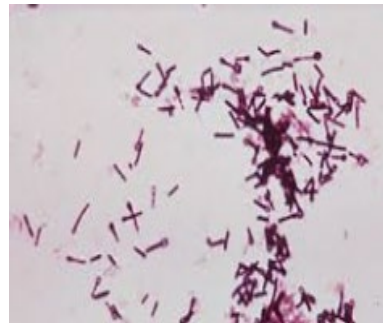1. Record your candidate number and HSD discipline on the front sheet of the answer booklet.
2. Record your candidate number, the question number and the page number in the spaces provided on the answer sheets.
3. Begin each new answer on a new page.
4. Each question is worth 25 marks.

1. Identify each of the following nine images and select which is a potential Category 3 pathogen, as well as the clinical significance of these findings:

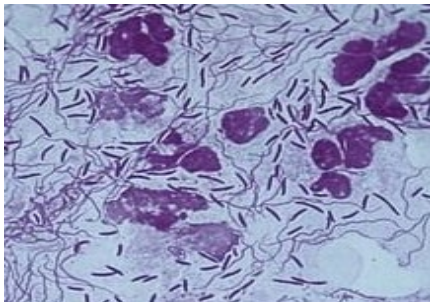
a.



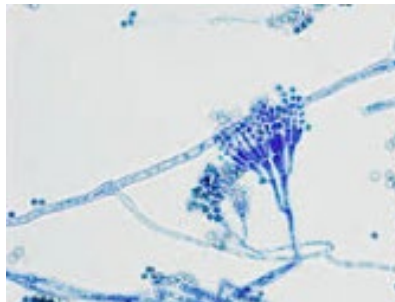
b.



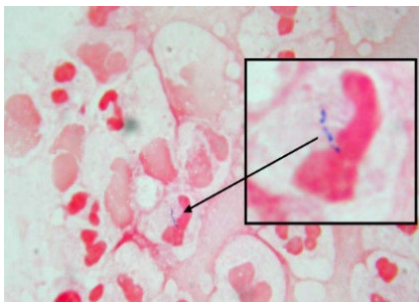
c.



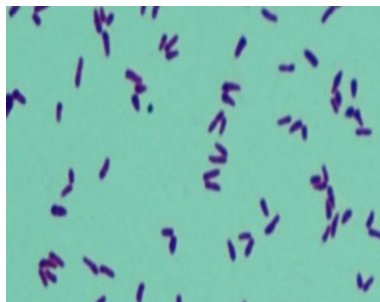
d.



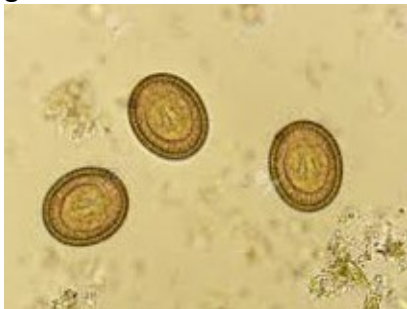e.



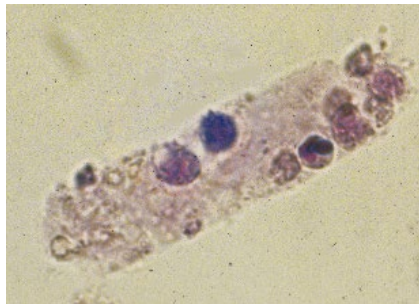
f.



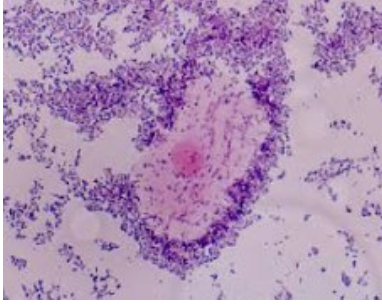
g.



h.



i.



2. Briefly describe the strategies used to optimise recovery of bacteria from blood culture bottles.
  
3. The Emergency Department in the hospital consistently fails to submit samples that are compliant with the Laboratory Sample Acceptance Policy. Describe how you could approach this issue?
  
4. Disc diffusion methodology is no longer appropriate for AST in a modern microbiology laboratory. Discuss this statement.



**Higher Specialist Diploma**

**Medical Microbiology**

**Examination – September 2023**

**Essay Paper**

120 minutes

**Attempt 2 out of 5 questions**

Instructions to candidates

1. Record your candidate number and HSD discipline on the front sheet of the answer booklet
2. Record your candidate number, the question number and the page number in the spaces provided on the answer sheets
3. Begin each new question on a new page
4. Each question is worth 100 marks

1. Discuss the role the host immune status plays in the pathology of an Aspergillus infection that begins in the lungs and describe how you can treat the various outcomes.
2. Is the UK prepared for a novel bacterial HCID? Discuss the current model of service delivery and access to sequencing.
3. What is sepsis and how can Microbiology services be delivered to focus on reducing cases of sepsis.
4. Critically analyse the economical and clinical aspects of fungal antigen markers in healthcare provision.
5. Critically discuss the clinical challenges of high-level aminoglycoside resistant Enterococci infections and compare and contrast the laboratory techniques used to identify these organisms.



## **Higher Specialist Diploma**

### **Medical Microbiology**

#### **Examination – September 2023**

##### **Case studies**

120 minutes

##### **Attempt all case studies**

##### Instructions to candidates

1. Record your candidate number and HSD discipline on the front sheet of the answer booklet
2. Record your candidate number, the question number and the page number in the spaces provided on the answer sheets
3. Begin each new case study on a new page
4. Each question is worth 100 marks
5. For these case study questions you are strongly advised to answer the questions as they arise during the case study to avoid later information impacting adversely on your answers to the earlier questions by presuming an “outcome”

## SEEN CASE STUDY

1.

Mr H is a 54-year-old Swiss gentleman visiting family and friends in the UK. During his holiday he suddenly became unwell. His temperature was raised and he complained of shortness of breath. Mr H informed his relatives that he had recently been feeling fatigued with non-specific joint and muscle pain. He thought it was just a bug that had been going around. However, his family were now becoming increasingly worried, particularly as Mr H underwent cardiac surgery three years earlier. They decided to take him to the local A&E for an assessment.

- a. Solely from the ABOVE scenario provide a differential diagnosis for this patient. (10 marks)

Mr H informed the A&E clinicians that he underwent a mitral valve replacement with good post-operative recovery, during surgery he had been placed on cardiopulmonary bypass (CPB). He had returned to work 6 months after surgery. He said that he had only started feeling tired and breathless a few weeks ago.

- b. Explain, with the aid of diagrams, the principles of this the cardiopulmonary bypass supportive procedure, and discuss the infection control risk associated with CPB usage. (25 marks)

On further examination his surgical site appeared slightly red and warm to the touch. In addition, his echocardiogram showed vegetation on his mitral heart valve. Mr H was admitted to the cardiothoracic ward for treatment.

- c. Outline which sample(s) would be taken to confirm an infective cause and indicate how they would be processed in the laboratory. (25 marks)

Both direct and enrichment cultures were negative after 48 hours incubation.

- d. Consider any further tests in accordance with those recommended by the Standards of Microbiology Investigations. (10 marks)

A slow growing, non-tuberculous mycobacterium is recovered from liquid culture after 35 days continuous incubation. The organism is confirmed as belonging to the Mycobacterium avium / intracellulare complex.

- e. What is the likely causative organism? Indicate how to collect and process the environmental samples required to prove this is a nosocomial infection. (30 marks)

## UNSEEN CASE STUDIES

2.

A 35-year-old Caucasian male patient presented to his general practitioner with pain and swelling in both wrists and his right knee. He explained that he had been suffering from these symptoms for the past three weeks.

The patient's past medical history included a diagnosis of Wilson's disease at the age of 21, a liver transplant as a result of cirrhosis at the age of 25, hypertension, diabetes, and renal insufficiency (230  $\mu\text{mol/L}$ ).

He also suffered an intrahepatic abscess six months previously; from which the microbiology samples isolated an *Enterococcus faecalis*. Treatment for his intrahepatic abscess included drainage and prolonged parenteral ampicillin and gentamicin through a Hickman line.

His current treatment regimen includes prednisolone 10mg OD, mycophenolate mofetil 1g BD, insulin and pindolol.

On examination, the patient was suffering from pyrexia (temperature of 38.5°C) and inflammation of both wrists was observed however, the patient did not experience any limitation in the range of motion. A large effusion was present on the right knee resulting in limited movement.

- a. Based only on the information provided above, evaluate the past medical history, the current symptoms, possible infection present and devise an investigative strategy. (25 marks)

Due to the initial symptoms observed, a blood sample, synovial fluid and blood cultures were collected. X-rays of both hands, wrists and knees were performed. The results revealed an elevated white blood cell count (White Blood Cell count  $13.2 \times 10^9 / \text{L}$ ) with the white blood cell differential indicating increased neutrophils.

The erythrocyte sediment rate was also increased and the C-reactive protein level was 65 mg / L. Blood culture results were negative at 48 hours and the hand, wrists and knee x-rays were normal.

- b. Discuss how the joint fluid would be analysed within the microbiology laboratory. (20 marks)

No organisms were identified in the synovial fluid Gram stain and no crystals were observed. Blood culture samples remained negative. Culture plates from the synovial fluid grew *Enterococcus faecalis*, *Enterobacter sakazakii* and *Candida albicans*. An abdominal MRI scan revealed no hepatic abscess however, a left wrist MRI revealed extensive inflammation.

- c. Discuss a definitive diagnosis for this patient. In your answer consider the potential origin of each of the organism's associated with this patient's polymicrobial infection and



how any risk factors associated with this patient history may have been contributing factors. (25 marks)

- d. Consider the advantages and disadvantages of rapid identification techniques when isolating more than one organism from a sample. (20 marks)
- e. Consider the treatment regimen that this patient would benefit from. (10 marks)

3.

A 22-year-old Chinese male was in the UK for several weeks visiting friends. He had been in the UK for 3 weeks without any symptoms. He attended his local emergency department complaining of severe headaches and blurred vision.

He self-discharged prior to a full examination. One week later he was brought back to the emergency department by his friends because he now had convulsions, confusion and was febrile now.

- a. Based on the information above what investigations should be performed? (10 marks)

The FBC results showed a raised WBC with raised neutrophils and a CRP of 120. The imaging of the brain showed a 28mm parietal abscess. The patient was transferred to a specialist neurology unit to aspirate the abscess.

The clinical team have also been informed by the patient's friends that he suffers from Evans Syndrome is on long term prednisolone and has specialist infusions of Rituximab.

- b. Describe some of the complications of this type of surgery. What are the consequences of Evans disease and how might that affect the aetiology of infection? (20 marks)

The procedure collected approximately 1ml of mucoid fluid.

- c. Describe how this sample would be processed in the Microbiology laboratory considering the patients history. (10 marks)

The blood culture remained negative at 48 hours. After extended incubation the aspirated pus started to grow white, chalk-like colonies on the blood agar and chocolate plate. A Gram stain result showed that these were branching Gram positive bacilli, with a beading effect.

- d. What tests could be performed to identify this organism. (10 marks)

As there was no growth after 48 hours 16s PCR was performed on the original sample which identified 99% homology with *Nocardia asiatica*. Which was consistent with MALDI-TOF identification yielded after sufficient growth on solid media.

- e. Describe the pathology of nocardiosis in relation to our patient and first line treatment regimes. (20 marks)
- f. *Nocardia* sp has often been mis-identified as *Mycobacterium* sp. Describe why this might be, and what is available now to make this differentiation. (20 marks)

The patient has had the abscess drained and is on appropriate antibiotic therapy, and his neurological symptoms begin to improve.

- g. Which follow-up, outpatient care and monitoring tests should be performed? (10 marks)