



Higher Specialist Diploma

Cytopathology

Examination 2017

Seen Case Study

1. This seen case study will be the first question in the case studies examination.
2. There will be a further two unseen case studies in the examination.
3. Candidates should note that whilst they should spend time between the publication of the case study and the examination preparing their responses they are **not** permitted to take any prepared answers into the examination room.

Seen Case Study

1. A 60-year-old male presented with multiple episodes of haematuria and attended his GP for advice. He was referred urgently to the urology clinic. The patient was assessed with cystoscopy which showed inflammation only. Urine cytology taken before the cystoscopy showed presence of scanty “atypical cell clusters”

He had imaging studies (CT IVU) which showed a filling defect in the left ureter.

- a. What do you understand by the term “filling defect”? What are possible differential diagnosis? (20 marks)

The urologist carried out selective urothelial washings from the left and the right ureter.

- b. Briefly describe how ureteric washings are taken. (10 marks)

The samples were sent to cytology laboratory and cytospin preparations were made. Images 1 and 2 are from the left ureter and images 3 and 4 from the right.

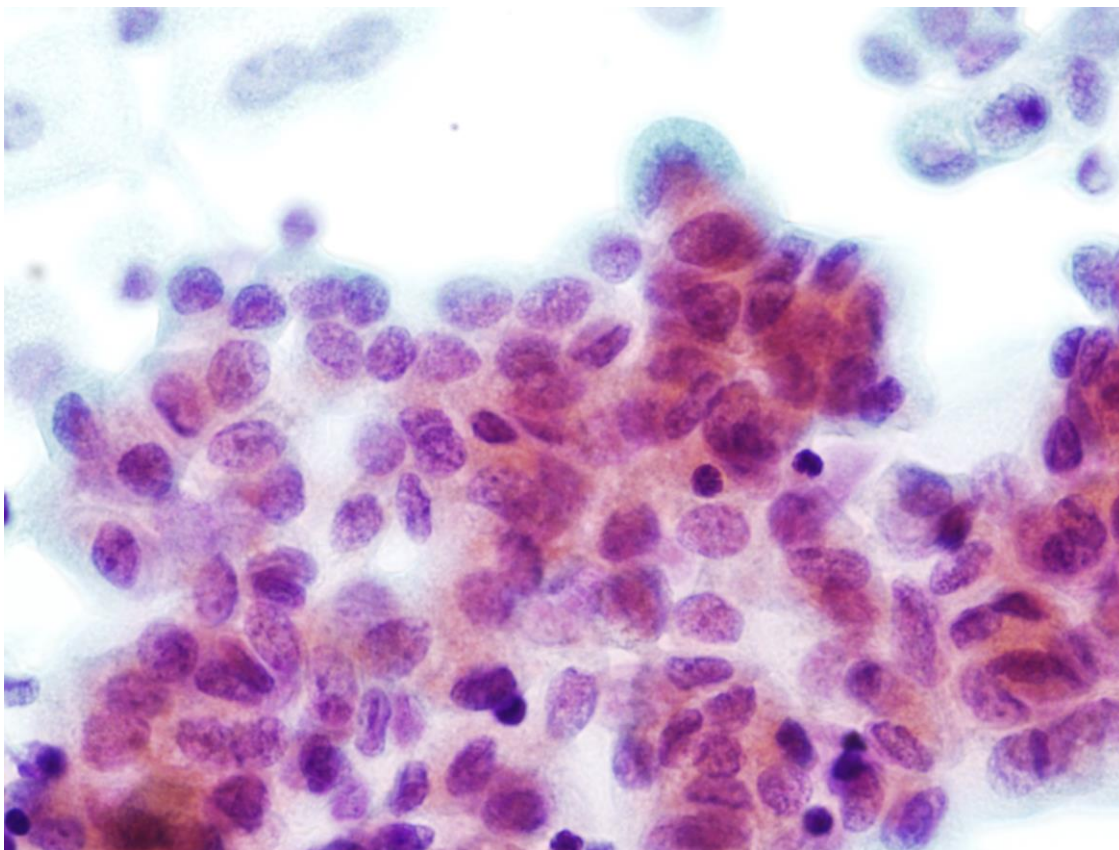


IMAGE 1

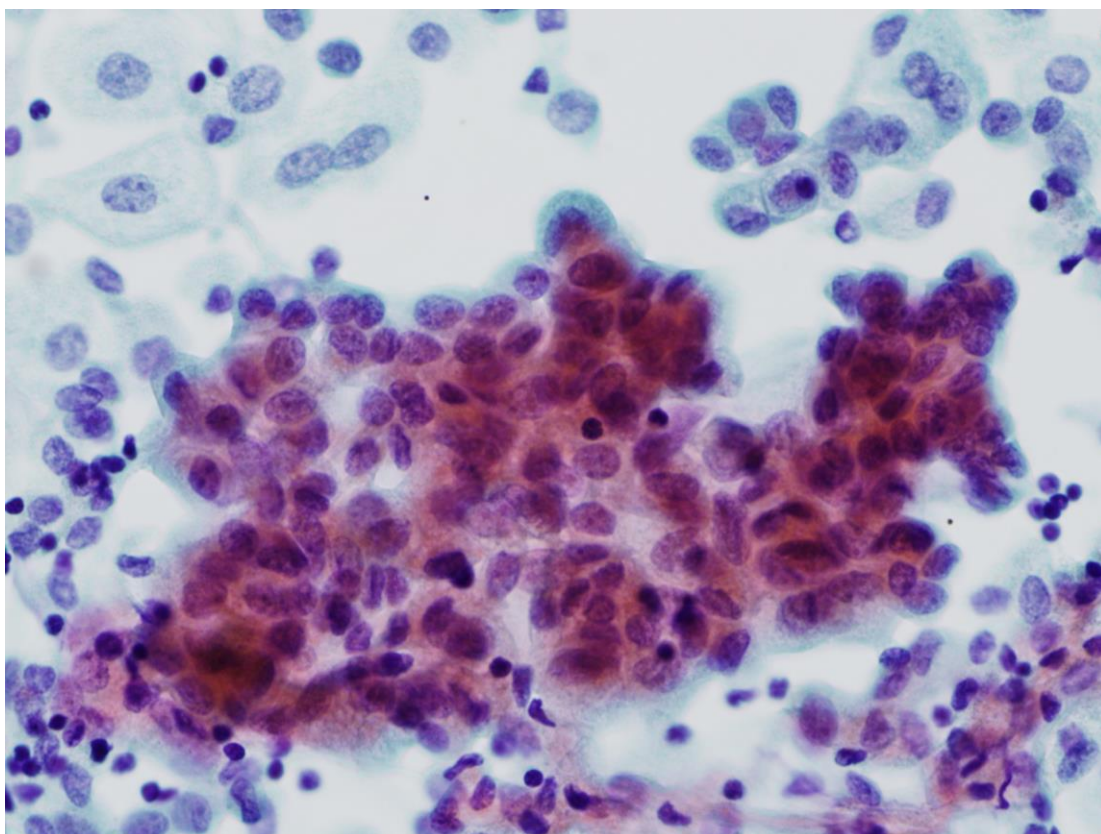


IMAGE 2

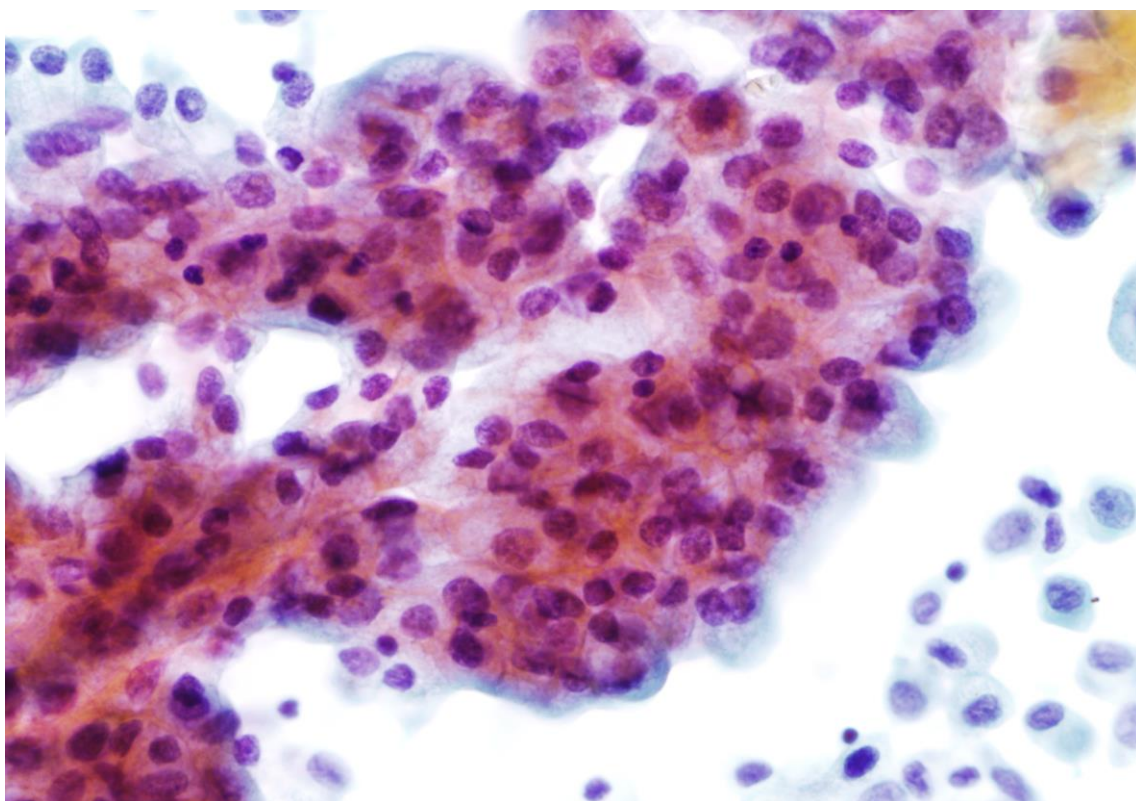


IMAGE 3

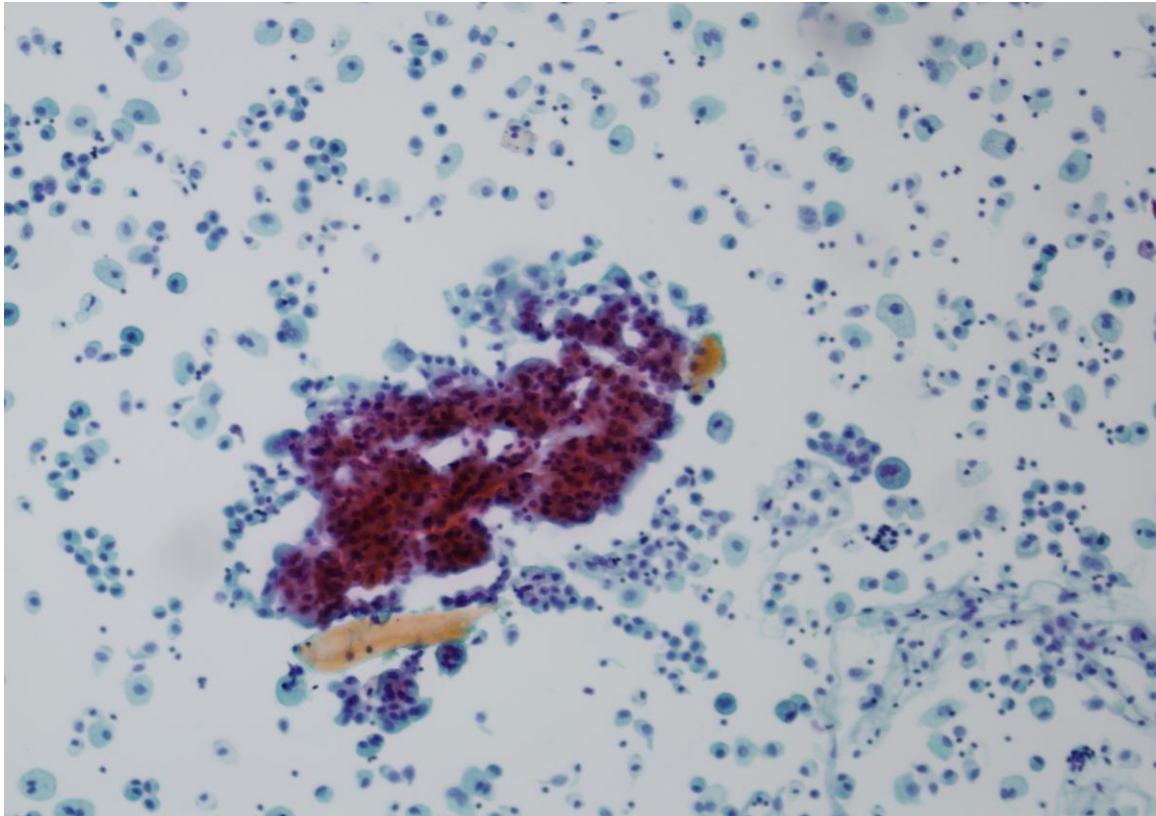


IMAGE 4

- c. Review the images and describe and discuss the cytological features, and suggest a diagnosis. (40 marks)
- d. Discuss the term iatrogenic changes and how does sample type in urine cytology affects cellular presentation. (30 marks)